SonoPath
Clinical Sonography & Telecytology
EDUCATIONAL TELECONSULTATION SERVICES™
1-800-838-4268 info@sonopath.com SonoPath.com

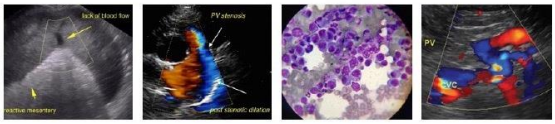

THE FOCAL ZONE
IMAGING PERFORMED BY
289-808-2608 info@thefocalzone.com

PATIENT
Molly Kirk

SPECIES
Canine

BREED
Cavalier

SEX
Female Spayed

AGE
9 years

WEIGHT
19.6lbs

INTERPRETED BY
Maggie Machen Lamy, DVM DACVIM (Cardiology)

IMAGING PERFORMED BY
Crystal Hill, RVT

HOSPITAL NAME
Dundas Animal Hospital

REFERRING VET
Dr. Middleton

INVOICE
30144

DATE
4/10/23

PRESENTING CLINICAL SIGNS

History: Recheck echo, grade 5/6 heart murmur.
-Pertinent previous echo findings (12/2021 MML): Mild MR, mild LAE, mild TR: 2.4m/s. LA: 2.2, LV: 3.0.

ECHOCARDIOGRAM FINDINGS

2D, m-mode, color flow and doppler imaging is available. Mild thickening of mitral valve leaflets with mild prolapse into the left atrial lumen. Moderate eccentric mitral regurgitation with moderate left atrial dilation. Normal MR velocity. Mild LV dilation with hyperdynamic myocardial function. The tricuspid valve appears mildly thickened with mild tricuspid regurgitation. Velocity consistent with early pulmonary hypertension. Normal right atrial and ventricular diameter and morphology. The pulmonic and aortic valves are normal in morphology and mobility. Normal pulmonic and aortic outflow velocities with laminar flow. No obvious aortic or pulmonic insufficiency. No pericardial or pleural effusion noted. No obvious cardiac masses.

CARDIAC CHART

CANINE CARDIAC PARAMETERS	MR VMAX (m/s)	TR VMAX (m/s)	LA/AO (Boon method)	LA/AO (Heart Base; Swe)	FS (%)	EF (%)	EPSS (cm)
NORMAL PARAMETER	4.5-5.5	<2.7	1.3	<1.6	28-40	40-100	<0.6
PATIENT	6.0	3.0	NM	1.7	55	86	0.3
CANINE CARDIAC PARAMETERS	**HR** (BPM)	**AV VMAX** (m/s)	**PV MAX** (m/s)	**BODY WEIGHT** (kg)	**LA** 2D short axis Base view (cm)	**LVIDd** Avg; 2D and m-mode short axis (cm)	**LVIDs** Avg; 2D and m-mode short axis (cm)
NORMAL PARAMETER	50-100	0.7-1.7	0.7-1.6	BELOW	BELOW	BELOW	BELOW
PATIENT	150	1.6	1.6	8.9	2.7	3.9	1.7

*Normal chamber parameters expressed as a mean value (SD)

BODY WEIGHT DEPENDENT PARAMETERS

**Note: All measurements based upon multi-modal images and methods. An average value is reported.*

Adapted from June Boon, Veterinary Echocardiography, 1998
Rishniw M and Hollis NE, J Vet Intern Med 2000; 14:429-435
Hansson et al, Vet Rad and Ultrasound 2002
Bonagura et al. Echocardiography: principles of interpretation, Vet Clin North Am 15:1177, 1995

3	1.27 (5.3)	2.46 (2.46)	1.36 (5.5)
5	1.40 (4.5)	2.74 (5.2)	1.60 (4.7)
10	1.50 (3.8)	3.27 (3.5)	2.06 (3.1)
15	1.83 (2.0)	3.71 (2.4)	2.43 (2.1)
20	2.02 (1.9)	4.14 (2.2)	2.80 (2.0)
25	2.18 (2.4)	4.48 (2.9)	3.10 (2.5)
30	2.33 (3.3)	4.83 (3.9)	3.39 (3.4)
35	2.48 (4.3)	5.17 (5.0)	3.69 (4.5)
40	2.62 (5.2)	5.48 (6.1)	3.96 (5.4)
50	2.88 (7.1)	6.07 (8.3)	4.46 (7.4)

INTERPRETATION OF THE FINDINGS & FURTHER RECOMMENDATIONS

Chronic degenerative valve disease persists with evidence of progression. Previously mild MR has advanced to moderate, with increasing left heart dimensions. The tricuspid leak is stable, although early pulmonary hypertension has developed which should be monitored going forward. Moderate left atrial enlargement indicates there is relatively low risk for imminent complication, however risk for progression to spontaneous congestive heart failure in the future is elevated.

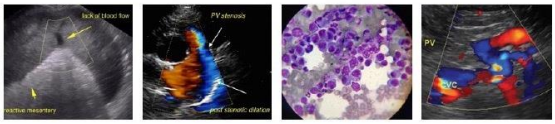

PATIENT
Molly Kirk

SPECIES
Canine

BREED
Cavalier

SEX
Female Spayed

AGE
9 years

WEIGHT
19.6lbs

INTERPRETED BY
Maggie Machen Lamy, DVM DACVIM (Cardiology)

IMAGING PERFORMED BY
Crystal Hill, RVT

HOSPITAL NAME
Dundas Animal Hospital

REFERRING VET
Dr. Middleton

INVOICE
30144

DATE
4/10/23

Based upon these findings, recommend institution of Pimobendan as below. Additionally, a baseline BP is recommended. Continued assessment of progression is recommended, with a guarded prognosis going forward (stage B2). Patient may be at risk for development of CHF, arrhythmias, and/or sudden death going forward.

Omega fatty acid supplementation and mild salt restriction may also be of some long-term benefit. Monitor for development of a progressive cough, labored breathing, exercise intolerance or collapse episodes.

Once on the medication for 3-5 days, anesthetic risk remains mildly elevated. Cardiac protective drug choices (opioid/benzodiazepine premedication, Propofol or alfaxalone induction, iso or sevo gas) are recommended. Monitor for arrhythmias, hypotension, and hypoxia both intra and post-operatively and intervene as necessary. Judicious IV fluid rates are recommended to avoid fluid overload. Avoid heart rate stimulating drugs such as atropine unless clinically indicated.

PLAN

Baseline BP recommended every 6 months. Institute Pimobendan 0.25-0.3mg/kg PO q12h.

Recommend monitor for progression with a recheck echocardiogram in 6 months, sooner if any development of clinical signs.

IMAGES

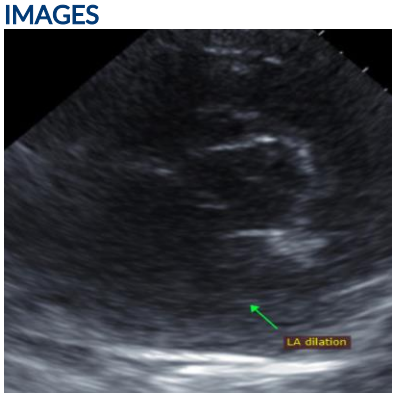

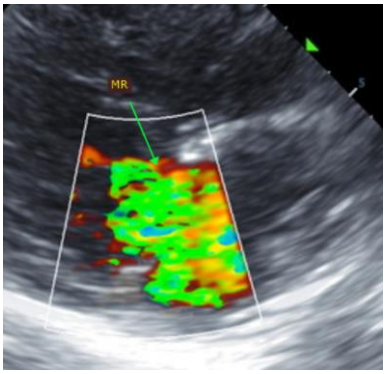

The information and recommendations provided are based on the images presented by the referring veterinarian. No evaluation can be communicated regarding pathology that was not visible in the image/video clips provided.

Thank you for this referral. This report was generated using transcription software, and minor dictation errors may be present. If the clinical or image interpretation does not parallel your findings or if I can be of any further assistance, please contact me.

Maggie Machen Lamy, DVM
Diplomate of the American College of Veterinary Internal Medicine (Cardiology)
info@sonopath.com

SonoPath
Clinical Sonography & Telecytology
EDUCATIONAL TELECONSULTATION SERVICES™
1-800-838-4268 info@sonopath.com SonoPath.com

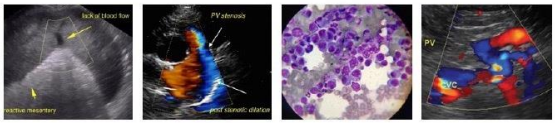

THE FOCAL ZONE
IMAGING PERFORMED BY
289-808-2608 info@thefocalzone.com

PATIENT

Molly Kirk

SPECIES

Canine

BREED

Cavalier

SEX

Female Spayed

AGE

9 years

WEIGHT

19.6lbs

INTERPRETED BY

Maggie Machen Lamy, DVM DACVIM (Cardiology)

IMAGING PERFORMED BY

Crystal Hill, RVT

HOSPITAL NAME

Dundas Animal Hospital

REFERRING VET

Dr. Middleton

INVOICE

30144

DATE

4/10/23